Stifle Lameness in the horse

by Eugenio Cillán-García

Stifle problems are a relatively infrequent cause of lameness in horses. An increasing number of conditions affecting this region are, however, being recognised and being diagnosed more accurately with advances in imaging technology. Acute stifle lameness often results from direct trauma or is associated with exercise where abnormal rotation forces may act on the joint.
Clinical signs vary from horse to horse. The degree of lameness is variable from very mild to very severe non-weight bearing depending on which structure or structures are affected. Muscle wastage may or may not be present at the time of the examination; when present it normally is an indication of a long term problem. Swelling of the soft tissues around the stifle region or distension of the joints can be subtle or obvious.

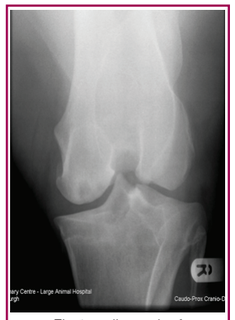

Fig 1. radiograph of subchondral bone cyst on inside of the femur

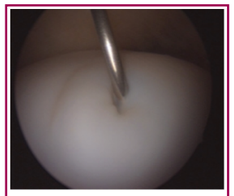

Fig 2. Arthroscopy view of the same bone cyst. The metal probe is exploring the depth of the defect

A meticulous and systematic lameness examination needs to be carried out to identify the source of lameness. Both static and dynamic evaluations of the horse at walk and trot in a straight line in a hard surface and in a soft and hard surface in the circle are necessary to assess the degree of lameness.

Nerve blocks are necessary when there are no obvious indications that the lameness is localized to the stifle region. Joint anaesthesia ('joint block') is normally used to localize the lameness specifically to the stifle. The stifle joint is the largest, most complex joint in the horse and is divided in 3 compartments, the femoro-patellar joint, the lateral femoro-tibial joint, and the medial femoro-tibial joint. Mild to moderate improvement in lameness after a joint block is an indication of a stifle problem, however some acute injuries do not respond to joint blocks.

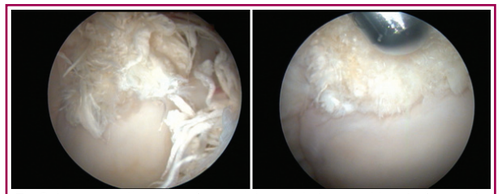

Fig 3: Intra-operative view of a cranial cruciate ligament tear before and after cleaning up with a motorized tool which removes frayed tissue and so minimises the likelihood of severe arthritis.

After localization of the lameness or when a problem is suspected in this area, radiography is often the first diagnostic technique used. Radiographs are a useful tool to identify osseous problems such as osteochondral lesions, subchondral bone cyst or fractures, but the sensitivity to detect soft tissue injuries and cartilage lesions is poor. Ultrasonography is the only non-invasive technique to evaluate the soft tissue structures of the stifle. Nuclear scintigraphy ('bone scans') can be useful in some cases. Surgical arthroscopy, i.e keyhole surgery, has become an essential tool in the diagnostic evaluation and treatment of stifle joint disease, just like in human knee injuries. Injuries such as cartilage lesions, cruciate ligament tears or meniscal damage are difficult to appreciate with other diagnostic modalities. Arthroscopy of the stifle joint is necessary to assess the extent of soft tissue injuries **allowing a more accurate prognosis and maximising the formulation of treatment plans**. Some horses with even very extensive cartilage damage may return to athletic function after arthroscopic debridement and lavage. A more pessimistic prognosis may be given to older horses, those with more severe pre-operative lameness, and those with severe radiographic changes or arthroscopic findings such as large meniscal tears.

The practice is on Facebook and Twitter. Follow us for the latest news and information.

Facebook.com/DickVetEquine **@DickVetEquine**

Our veterinary surgeons

Jenny Clements
BVSc MSc Cert EIM MRCVS

Eugenio Cillán-García
LV MRCVS

Louise Cornish
BVMS Cert EP MRCVS

Tess Fordham
BVMedSci BVM BVS MRCVS

Ably assisted by our team of excellent hospital residents

Front office staff

Trish O'Donnell, Morven Kerr, Joanne Smith

THE ROYAL (DICK) SCHOOL OF VETERINARY STUDIES

THE DICK VET EQUINE PRACTICE

0131 650 6253 **www.DickVetEquine.com**

SPRING 2014

CONTACT

The Dick Vet Equine Practice

The Royal (Dick) School of Veterinary Studies
The University of Edinburgh
Easter Bush Campus
Midlothian, EH25 9RG

tel: 0131 650 6253
out of hours tel: 01223 849 835
fax: 0131 650 8824
web: www.DickVetEquine.com
email: EQH@ed.ac.uk

The University of Edinburgh is a charitable body, registered in Scotland, with registration number SC005336.

RCVS ACCREDITED PRACTICE EQUINE HOSPITAL

Welcome to our Spring 2014 newsletter.

2014 promises to be a much more settled year as we are now at full strength again, with an excellent, reliable and forward-thinking team, which comprises 2 equine certificate holders (Jenny and Louise), one expert in lameness/surgery (Eugenio) and our excellent intern Tess who is proving to be an extremely valuable team member.

Inside this edition of the newsletter, you will find some interesting articles on stifles and sarcoids. Stifles are the equivalent of our knee joints and although not as common as, for example problems in the foot, we seem to see more and more problems associated with this area. Sarcoids of course are a very common skin disease and the article written by Jenny is to complement our first DVEP Practice Evening of the year on the very same topic, presented by Professor Derek Knottenbelt. Professor Knottenbelt is a very well-known and respected equine vet who has had particular interest over the years in equine sarcoids. His talks are always full of information and entertaining to boot. In addition, Louise Cornish will talk about her recent trip, helping out at the Gambia Horse and Donkey Trust. We hope you can join us on the 23rd April for what promises to be an excellent evening. The evening is free, as usual, but anyone who wishes to make a donation to Derek's Charity (Vets with Horsepower) is very welcome to do so.

Another event to look out for is our Laminitis Practical Day which will take place on the 3rd May. We will be looking at ways to prevent laminitis in your horses and ponies, discussing signs of Cushing's disease and showing you how to body condition score effectively as well as offering nutrition advice. As a University, we are very proactive in laminitis education and research and the event will utilise the expertise of the practice, hospital and research clinicians. We hope to see you there as well.

DVEP Client Events

23rd April 2014

"EQUINE SARCOIDS" Presented by Professor Derek Knottenbelt

Professor Knottenbelt is a world renowned expert in equine medicine and has developed a particular expertise in sarcoids through his work at Liverpool University

PLUS: Louise Cornish will talk on her trip to the Gambia helping out at the Gambia Horse and Donkey Trust

The event is free but donations are gratefully received towards Derek's charity 'Vets with Horsepower' which raises money for the Gambia Horse and Donkey Trust and The Smile Train.

The talk is being held in the teaching building at the Easter Bush Campus. We're putting on refreshments from 7pm and the talks will begin at 7:30pm - everyone is welcome!

3rd May 2014

LAMINITIS PRACTICAL DAY

Hungry Hippo or hormonal issues? Is metabolic testing the answer?

Practical Stations
- Ultrasound demonstration • The weight loss ideas stable
- Appropriate exercise for effective weight loss

Interactive Sessions
- Body Condition Scoring • Weighing and new technologies
- Metabolic testing case studies

Displays and Talks
- Ask the Expert panel • Cushings (PPID) • Forage analysis
- Nutritional advice and displays • Laminitis - new advances and current research • Providing nutrients for weight loss cases

The day is **free** and will run 10am to 2pm at the Easter Bush Campus. Refreshments will be provided. Check our website for full details.

Please call our reception on 0131 650 6253 or email EQH@ed.ac.uk to book a place at either of these events or if you have any questions

Sarcoids

by Jenny Clements

What is a Sarcoid?

Sarcoids are the most common skin tumour affecting horses worldwide. They vary greatly in size, appearance, location and response to treatment. They are confined to the skin and do not spread to the internal organs but nonetheless, can be a challenge for owners and veterinary surgeons.

The cause of sarcoids is still not fully understood but the bovine papillomavirus is widely accepted as being significant. There is also evidence that flies play an important role in the pathogenesis.

Sarcoid facts

- Sarcoids are common.
- Sarcoids are a type of skin tumour.
- Once a sarcoid horse, always a sarcoid horse – a horse with a sarcoid is liable to develop more.
- Sarcoids can develop anywhere on the skin but commonly affect the chest, groin, sheath and eyes.
- Trauma to a sarcoid may aggravate it.
- No two sarcoids are the same, each needs to be assessed on an individual basis.
- Treatment is not always necessary but if required, can be difficult and expensive and is not always successful.
- Sarcoids may recur, despite treatment.

Types of sarcoid

There are 6 distinct clinical entities, namely; occult, verrucose (warty), nodular, fibroblastic, malevolent and mixed sarcoids.

Occult

Lesions are hairless, often circular and easily mistaken for ringworm lesions or rubs from tack. They are seen on the relatively hairless areas such as the face, neck, chest and groin.

Fig 1. Occult

Verrucose

Verrucose sarcoids have a "wart-like" appearance, are often grey in colour and may have a cracked or flakey appearance.

Fig 2. Verrucose

Nodular

Nodular sarcoids are firm round lumps that appear anywhere on the horse's body but commonly in the axilla (armpit), thigh, groin, sheath and eyelid. They are normally covered by skin and can be freely mobile underneath it or firmly adhered to it. In some cases, the overlying skin can be ulcerated.

Fig 3. Nodular

Fibroblastic

Fibroblastic sarcoids have a characteristic fleshy, aggressive and ulcerated appearance. They are commonly found in the axilla, groin, sheath, eyelid and lower limb. They may easily bleed and can look like "proud flesh". Indeed, they can occur at sites where there has previously been a wound (especially if there are sarcoids elsewhere on the horse) or develop rapidly from occult, verrucose or nodular sarcoids which have been traumatised.

Fig 4. Fibroblastic

Malevolent

The malevolent sarcoid is the most aggressive form of sarcoid. Its appearance is of multiple, invasive sarcoids, generally consisting of nodular and fibroblastic types. Although, malevolent sarcoids do not invade internal organs, they can be too aggressive to treat successfully. Fortunately, this type of sarcoid is rare.

Fig 5. Malevolent

Mixed

A mixed sarcoid is one that contains two or more of the sarcoid types.

DIAGNOSIS

The diagnosis of a sarcoid can usually be made on clinical appearance alone. For some forms of therapy, photos are taken and submitted to Liverpool University via their sarcoid submission website, who then recommends a suitable treatment protocol. Biopsies are rarely indicated in the diagnosis of sarcoids as surgical aggravation can turn a simple type into a more aggressive form. However, they are performed occasionally on sarcoids with an atypical appearance but we need to be prepared to treat these cases promptly if a diagnosis is subsequently made.

TREATMENT

There are many reported treatments for sarcoids which in itself clearly demonstrates that no one treatment will be effective in each and every case. Each sarcoid should be assessed on an individual basis, by a veterinary surgeon. Inappropriate treatment can rapidly convert a simple sarcoid into an aggressive one. Treatment options include:

Watch and Wait

Occasionally a decision is made to monitor a sarcoid, rather than treat it. This is generally done on lesions which are small and have remained static for some time. An advantage is that the cost of treatment can potentially be avoided but consideration must be given to the possibility of spread of the sarcoid elsewhere on the horse or to other horses.

AW4-LUDES cream

This is our most commonly used sarcoid treatment and is also known as the "Liverpool sarcoid cream". It is a topical chemotherapy treatment that contains 5-fluorouracil, heavy metals, cytotoxic chemicals and natural plant oils. To obtain a prescription for this cream, photos need to be submitted through the Liverpool sarcoid submission website. We complete a questionnaire and upload photos of your horse's sarcoids through this website.

Liverpool charge a consultation fee (currently £20.74 + VAT) to examine the photos and issue a prescription. We automatically add this fee to your account at this stage. Once the prescription is issued, we contact you to advise you of the protocol and ask you to communicate directly with Liverpool to pay for the cream. The cost of the cream varies because Liverpool will sometimes prescribe a treatment course using more than one strength of cream. Once the cream is purchased, it will be dispatched to us and we will then ring you to book in dates for application. Only veterinary surgeons are permitted to apply the cream, due to its caustic nature. It is likely that 4-5 applications will be recommended at intervals of 24-72 hours. We usually suggest that we re-examine the horse or photos of the lesions at approximately 6 weeks post treatment. At this time, the treated area often looks like a hard plaque of dead tissue that will eventually drop off.

We normally re-submit photos at this stage (no consultation fee is incurred for follow-up photos). Liverpool advise us how to proceed and whether repeated courses of treatment are necessary.

It is worth noting that the submission procedure can take a little time and that the process is not an insignificant expense when you consider there are fees for the initial examination, Liverpool consultation, cream and applications. However, visit fees can be saved if you wish to bring your horse to the practice for each treatment. Additionally, some horses become quite sore during the treatment course and require sedation for the cream to be applied safely and anti-inflammatories to reduce the swelling and pain.

Surgery

Surgical options include sharp surgical excision, cryosurgery (freezing) and laser surgery. Surgery is only successful if the sarcoid is well defined and confined because you need a wide healthy margin to prevent recurrence. If this is not achieved, you can get rapid development of a fibroblastic sarcoid at the surgery site. Therefore, surgical options are rarely our first choice of treatment.

Ligation

Application of a ligature or band to a sarcoid with a well-defined "neck" can be very successful. This method is sometimes combined with application of the AW4-LUDES cream at the base to ensure complete removal of the sarcoid.

BCG Injection

Injection of BCG (used for human TB vaccination) works well for treatment of nodular sarcoids around the eye. It works less well at other locations.

As you can see, treatment of sarcoids is not always easy. If you would like to discuss sarcoids further, please do not hesitate to contact the practice on 0131 650 6253.